

Manual Small Incision Cataract Surgery (MSICS) Review of First 500 Cases Operated In Microsurgical Training Centre

Mir Zaman, Sofia Iqbal, M Younas Khan, M Tariq Khan, M Zahid Jadoon, M Babar Qureshi, M Amah Safi,
M Daud Khan

Pak J Ophthalmol 2006, Vol. 22 No. 1

See end of article for
authors affiliations

Correspondence to:
Mir Zaman
Senior Registrar
KIOMS, Hyatabad Medical
Complex, Peshawar

Received for publication
June 2005

Purpose: To evaluate the safety and efficacy of suture less manual small incision cataract surgery. (MSICS)

Material and Methods: A total of 500 patients having cataracts were recruited from out patient department of Khyber Institute of Ophthalmic Medical Sciences (KIOMS), Hayatabad Medical Complex (HMC) Peshawar from June 2003 to January 2004. After thorough examination and investigations the patients were operated in micro surgical training center (MSTC) by a single experienced surgeon using the same technique for all the patients. Their operative and postoperative complications, visual rehabilitation, astigmatism and co-morbidities were analyzed.

Results: Four hundred and twelve (82.4%) of the 500 patients completed the six weeks follow up. Three hundred and five (61%) had uncorrected visual acuity of 6/18 or better on first post-op day. Four hundred and seventeen (83.4%) had uncorrected visual acuity of 6/18 or better on 8th post-op day. Out of total 412 patients who presented for follow up after six weeks, 381 (76.2%) were the patients who had uncorrected visual acuity of 6/18 or better in the operated eyes.

Conclusion: MSICS is a safe and effective technique for the treatment of cataract patients in community eye care setting. It needs similar equipment as needed for conventional cataract surgery.

Cataract blindness is a major public health problem. Currently cataract is the world's leading cause of avoidable blindness affecting an estimated 20 million people¹. Because of the population growth and increased longevity, this figure is expected to increase to 50 million by the year 2020 if no additional interventions are implemented². The vast majority of the cataract blind people live in the developing world, in countries with limited resources. Many countries even today are not able to cope with the new cases, thus leading to rapidly growing backlog. To manage the large backlog of cataract blindness effectively, cost effective, high quality and high volume surgery is needed in community eye care

centers. The cost effectiveness is related to short operative time, potential for high volume, high success rates, and the low cost of consumables³.

However, when success rates are low, cost effectiveness is reduced⁴. This has led to calls for the quality of cataract surgery to receive at least as much attention as the quantity of surgery⁵. So alternative procedures which are affordable, practicable, applicable and sustainable everywhere can be adopted to obtain good outcomes in the settings of developing countries.

Cataract extraction accounts for more than half of the ophthalmic operations, and is the most elective operation in many countries around the world⁶.

Extra capsular cataract extraction with posterior chamber intraocular lens implantation (PC IOL) was the most frequent surgical technique until the past decade⁷.

The use of a smaller incision with the advantages of faster rehabilitation, less astigmatism and better postoperative vision without spectacles led to phacoemulsification becoming the preferred technique where resources are available⁸.

Although phacoemulsification has become the biggest surgical achievement of the present decade, the majority of surgeons in the developing countries are still not practicing it. One of important reasons for this is that the technique has a prolonged and sometimes risky learning curve. Moreover, most developing countries can not afford to buy and maintain a good phacoemulsifier and its allied expenditures⁹.

Innovations that are equally effective and safe are therefore urgently needed in the surgical management of cataract in the developing world¹⁰.

Switch over to phaco less and suture less cataract surgery, is quite exciting and interesting. The technique gives the advantages of early wound stability, minimal induced astigmatism, fast visual rehabilitation with a low complication rate and at an affordable cost. The method is simple and quick to perform as well. However, there is no doubt that suture less cataract surgery is slightly more difficult to learn than ab externo sutured extra capsular cataract extraction with posterior chamber intraocular lens implantation (ECCE with PC IOL). But converting to the technique for an experienced surgeon is not difficult. According to Bernd Schroeder ECCE surgeons needed a median of 58 operations, whereas phaco surgeons needed a median of 30 surgeries until they had completed the first MSIC operation independently¹¹. This was mainly because the later group already knew how to prepare the tunnel incision.

When changing from one technique to another, we also need to consider the costs of surgery, both to the provider and to the patient. An operation that gives better results but with a high cost will lead to unequal opportunities, as only the wealthy will be able to afford the better surgery¹².

MATERIAL AND METHODS

This prospective, single centered hospital based cohort study was conducted at Khyber Institute of

Ophthalmic Medical Sciences from June 2003 to January 2004. A total of 500 patients were operated by a single experienced surgeon using the same technique for all the patients. A special proforma was designed which was approved by Research Ethical Committee of Khyber institute of Ophthalmic Medical Sciences. All patients were included after obtaining their written consent. The inclusions criteria was, all patients with operable cataracts in one or both eyes affecting their routine activities.

Thorough preoperative evaluation of anterior and posterior segment was done using biomicroscopy and ultrasonography techniques.

Cases with RAPD, APD, corneal opacities involving more than 3x3 mm center of the cornea and retinal detachment as evident on B Scan ultrasonography were excluded from the study.

Systemic evaluation including blood pressure check up and diabetes screening were done. Blood samples of all patients were tested for hepatitis B and C virus. Keratometry and IOL powers were calculated using Helm holtz Keratometer and a Storz A scan. All variables were entered into the designed proforma. All surgeries were performed under peribulbar anaesthesia by giving 2 injections, mixture of xylocain 2% with adrenaline and bupivacain by two point's technique; 3 cc were injected inferiorly near the lateral 1/3 orbital margin and 3cc superiorly near the medial 1/3 orbital margin. Ocular compression was achieved with a piece of wet cotton swab.

STEPS

1. The Incision

There are three parts to this vertical scleral incision, the tunnel fashioning and opening into cornea (Fig.1).

The Scleral Incision

A superior rectus suture is inserted, a fornix based conjunctival flap dissected and bleeders secured by wet field cauterization. A frown shaped half thickness scleral incision is made using a No.15 disposable blade. The center of incision is 2mm and its extremities 4mm away from the limbus. The cord subtended by the arc shaped incision is 5.5 to 6.5mm in length depending on the size of the nucleus. Maximum care is taken to avoid dissection of perforating veins in order to prevent intra operative bleeding. This type of incision does not need suturing because the large distance between the internal and external opening (at least 4 mm) makes the wound self-sealing as the

intraocular pressure rises. Therefore, the length of the incision does not really matter.

Making the tunnel

This is the most critical part of incision. The incision is deepened to half of the scleral thickness and scleral tunnel fashioned from its base to about 1.5-2 mm into the clear cornea using a crescent knife. This produces a tunnel which stretches from 10 o'clock and 2 o'clock position and which is about 1.5-2 mm larger than the outer opening.

Completing the incision into the anterior Chamber

The incision is completed after making a side port and completing the capsulotomy. A 3.2 keratome is used to enter the anterior chamber (AC) at the corneal end of the tunnel. The incision is completed with the sharp edge of keratome. It is much easier and safe to cut against a firm eye than a soft eye, so it often helps to fill the anterior chamber with viscoelastic material through the side port.

2. Side Port Entry

A 3.2 mm keratome is used to make a side port entry at the limbus to facilitate the introduction of second instrument, injection of viscoelastics before capsulotomy, aspiration of residual lens matter at 12 o'clock position, removal of viscoelastics and reformation of anterior chamber at the end of surgery.

3. Capsulotomy

Capsulotomy is performed with the help of 26 or 30 G disposable needle or cystitome. Cystitome is entered into the anterior chamber through limbus at 10 O'clock position and K-2 capsulotomy (V-Capsulotomy) or continuous curvilinear capsulorhexis performed depending upon the type of cataract. The tunnel incision is completed after anterior capsulotomy.

4. Hydrodissection/Hydrodelineation

This is a very essential step before nucleus delivery. It is carried out with 5ml syringe using curved 27G bent tip canula. The fluid is injected beneath the anterior capsule in one or two places, however, large volume and forceful injection should be avoided. Golden ring reflex in case of soft cataract or fluid waves are

observed which ensure complete hydrodissection. In this way, nucleus is prolapsed out of the bag at one end.

5. Nucleus Management

The nucleus is flipped up and rotated either with the help of the cannula which is used for hydrodissection and irrigating the area at the same time or it is rotated with the help of Sinsky hook after injecting viscoelastics into the anterior chamber. The nucleus is prolapsed into the anterior chamber, which is then extracted, by one of the following two techniques.

(i) Hydroexpression

Simcos irrigation/aspiration (I/A) canula is taken to 3 or 9 o'clock position into the anterior chamber and pressure is allowed to build up in AC, a little gentle counter pressure at 6 O'clock engages the nucleus in the wound. Further increase in pressure in AC pushes the nucleus out of the tunnel.

(ii) Visco-expression

In some cases specially when the nucleus is large and rock hard, viscoelastics is injected on either side of the nucleus as well as up and down. With pressure increase in AC, nucleus slips into the tunnel and ultimately outside the tunnel.

The cortical remnants are aspirated as usual using Simcos 0.5mm I/A cannula. Residual lens matter at 12 o'clock position is aspirated through a side port usually at 9 o'clock position.

6. IOL Implantation

Viscoelastic material is injected into the capsular bag and in AC before IOL implantation. The IOL used were mainly "Fredhollow Lenses" with 5.5mm optics and 13mm overall diameter. All IOLs were implanted either in the bag or in the sulcus depending on the status of the posterior capsule.

Keeping the anterior chamber inflated with viscoelastics or fluid from Simco's cannula, a vanna scissors is brought in with the other hand and slid over the top of the implant to the edge of capsular bag and a small cut is made in the flap. This torn edge is engaged in the canula or held with a plain tying forceps and a smooth capsular tear is made thus

completing the capsulorrhexis with the V Superiorly and smooth capsular tear at the base. Viscoelastic is aspirated and anterior chamber is reformed with balanced salt solution.

7. Closing The Conjunctival Flap

The conjunctival flap is closed with bipolar wet field cautery. The eye is then dressed with Tobramycin and Dexamethasone and patched overnight.

All the cases were operated as day cases and a new set of sterilized instruments was used for each case. A single pair of crescent knife and 3.2 keratome was used in succession to allow for optimum number of surgeries.

The patients had their first dressing changed the following morning. Visual acuities were recorded after removing the overnight dressing. Slit lamp biomicroscopy done and keratometry readings were recorded in all cases. Any operative or postoperative complications were also recorded in the predesigned proforma.

The patients were discharged and were requested to return for follow up examination after one week and 6 weeks. At 1 week and 6 weeks unaided visual acuity was recorded. Keratometry was performed and induced astigmatism was calculated. At follow up visits, patients were examined thoroughly and the cause of any uncorrected visual acuity less than 6/18 was recorded. All the data was analysed by an epidemiologist after feeding into a computer, using SPSS software.

RESULTS

Of the 500 patients entering the study, 272(54.4%) were male while 228(45.6%) were female. Mean age of the sample was 57.7 years with standard deviation of ± 12.2 years (Table 1) Patients came from different districts around Peshawar to get benefit from the microsurgical services at Hayatabad Medical Complex Peshawar (Table 2).

More than 77% of the patients had a pre-operative presenting visual acuity less than 3/60. In the remaining it ranged between 6/18 to 3/60 (Table 3).

Seventy percent of subjects had mature cataracts (LOCS III grading). The remaining had cortical

cataracts, posterior subcapsular in 6 % and nuclear cataracts in 4% cases (Fig 2).

The most common ophthalmic comorbidities were diabetic retinopathy 4%, glaucoma 3.2%, age related macular degeneration (AMD) 3% and corneal opacities 2%.

Of the total 500 patients having laboratory investigations, 4.2% were HBsAg positive and 3.6% were positive for HCV. Twelve percent of the patients had blood pressure more than 140/90 while 8.2% were diabetics.

Biometry was done in all cases. The mean axial length for this population was 23 ± 1.5 mm. The mean IOL power was 21.8 ± 2.8 D (IOL range from 19-25D). All the patients underwent the same surgical procedure. One hundred and fourteen (22.8%) patients had some complications during surgery. The most commonly occurring intraoperative complications were hyphaema and iridodialysis (Fig.3). The rate of occurrence of intraoperative complications decreased as the learning curve was crossed (Fig. 4). Seventy eight (15.6 %) of the patients developed postoperative complications from very mild to moderate severity (Table 4).

The study found that MSICS gave uncorrected visual acuity of 6/18 or better in high proportion of patients at discharge, first week and 6 weeks follow up (Table 5). Eighty eight patients were lost to follow-up (Table 5). Those who were lost to follow-up, 77% were in good vision (6/18-6/6) category, 18% had visual impairment (6/18-6/60) and 5.68% were blind at the end of first week follow-up. Fig. 5 best explains the comparison between preoperative and postoperative visual acuities of the study subjects. Amongst those who were blind, the main causes of blindness were ARMD (2 patients) and diabetic retinopathy (2 patients) while one patient was blind due to unknown reason. Preoperative and postoperative keratomeries were carried out in all patients at 1st week and 6 weeks follow-up. The mean preoperative astigmatism was 1.07. Analysis showed that mean postoperative astigmatism at first week and 6 weeks follow-up was 1.4 and 1.3 respectively. Post operative keratomeries showed astigmatism of minimum to 1.5D in 279 (55.8%) cases and >2D in 82 (16.4%) cases (Table 6).

Various causes for poor visual out come were also analyzed after 6 weeks of surgery (Table 7).

Table 1: Age distribution by gender

| Sex | Mean age (years) |
|---------|------------------|
| Males | 59.2 |
| Females | 56.2 |

Table 2: Age Distribution by gender

| District | No. of cases n (%) |
|-----------------|--------------------|
| Peshawar | 167 (34.4) |
| Afghan refugees | 99 (19.8) |
| Charsadda | 50 (10) |
| NWA | 44 (8.8) |
| Lakki Marwat | 24 (4.8) |
| Others | 116 (23.2) |
| Total | 500 (100) |

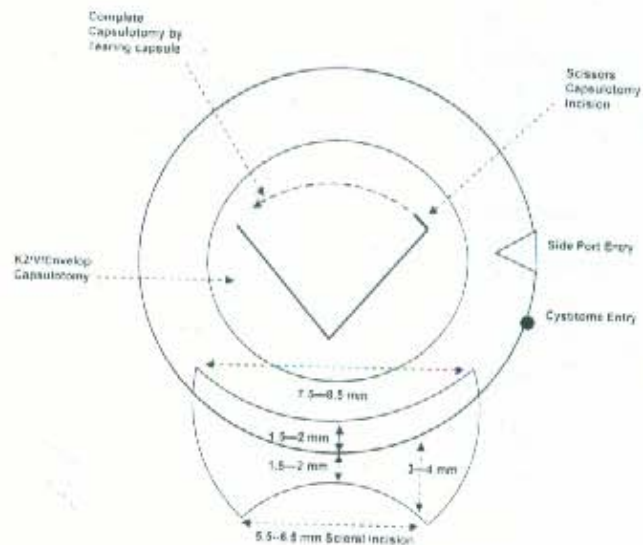


Fig. 1: Showing sutureless manual small incision cataract surgery. Sclerocorneal tunnel, side port entry, cystitome entry and capsulotomy technique.

Table 3: Pre operative visual acuity

| Visual Acuity | No. of cases n (%) |
|---------------|--------------------|
| 6/6 to 6/18 | 1 (0.2) |
| 6/18 to 6/60 | 110 (22) |
| 6/60 to 3/60 | 1 (0.2) |
| < 3/60 | 388 (77.6) |
| Total | 500 (100) |




Fig. 2: LOCS III Cataract grading

Table 4: Immediate post operative complications

| Type of complications | No. of cases n (%) |
|-----------------------|--------------------|
| Hyphaema | 51 (10.2) |
| Striate Keratopathy | 25 (5.0) |
| Wound Leak | 1 (0.2) |
| Endophthalmitis | 1 (0.2) |
| None | 422 (84.4) |
| Total | 500 (100) |




Fig. 3: Intra operative complications

Table 5: Preoperative visual acuity

| Visual Acuity | 1st postoperative day n (%) | 8th postoperative day n (%) | 6th week postoperative n (%) |
|---------------|--------------------------------|--------------------------------|---------------------------------|
| 6/6 to 6/18 | 305 (56.8) | 417 (83.40) | 381 (76.20) |
| 6/18 to 6/60 | 194 (38.8) | 74 (14.8) | 29 (5.8) |
| 6/60 to 3/60 | 0 (0.00) | (0.00) | (0.00) |
| < 3.60 | 22 (4.4) | 9 (1.8) | 2 (0.4) |
| Missing | 0 | 0 | 88 (17.6) |
| Total | 500 (100) | 500 (100) | 500 (100) |

Table 6: Astigmatism at 6th postoperative week

| Type of complication | No. of cases n (%) |
|----------------------|--------------------|
| < 0.50 D | 117 (23.4) |
| 0.50 to 1.0 D | 78 (15.6) |
| 1.0 to 1.50 D | 84 (16.8) |
| 1.50 to 2.0 D | 51 (10.2) |
| > 2.0 D | 82 (16.4) |
| Lost to follow up | 88 (17.6) |
| Total | 500 (100) |

DISCUSSION

Manual small incision cataract surgery has contributed considerably to accelerated wound healing, minimization of hospitalization and quick rehabilitation. Many patients travel for considerable distance to get advantage of facilities at MSTC, HMC, Peshawar. All the needy patients are provided with free IOLs, consumables and postoperative drugs. To obtain adequate follow-up all the study subjects were strictly advised.

Out of 500 cases, the most common cataract subtype was mature cataract in 350 (70%) cases which compares well with a similar study conducted by Hennig et al¹³, in which mature cataract constituted 72.8% of the total 500 patients. In another study conducted by Lewis et al¹⁴ nuclear cataract predominated as the subtype presenting before surgery, with pure nuclear and nuclear mixed with other subtypes accounting for nearly 90% of opacities.

Table 7: Causes for visual impairment and blindness after 6 weeks of surgery

| Causes | Visual impairment (6/18-6/60) n (%) | Blind (<3/60) n (%) |
|---------------------------|--|------------------------|
| ARMD | 5 (17.24) | 3 (75) |
| Pre existing corneal scar | 3 (10.24) | |
| Diabetic retinopathy | 5 (17.26) | 1 (25) |
| Hypheama | 1 (3.45) | |
| Increased IOP | 5 (17.24) | |
| Optic neuropathy | 2 (6.90) | |
| Bullous keratopathy | 1 (3.45) | |
| Unexplained | 7 (24.14) | |
| Total | 29 (100) | 4 (100) |

It means that most patients report late for surgery and thus the nucleus size is relatively big in developing countries cataract patients. So any technique, which involves multiple manipulations for fragmenting the nucleus makes the surgery more difficult with an increased chance of trauma to both the uveal and corneal tissues¹⁵. We extracted the nucleus enmass through a 5.5 to 6.5 mm scleral tunnel incision using hydro or visco expression technique without

fragmenting the nucleus in anterior chamber, thus minimizing the possible trauma to iris or corneal endothelium.

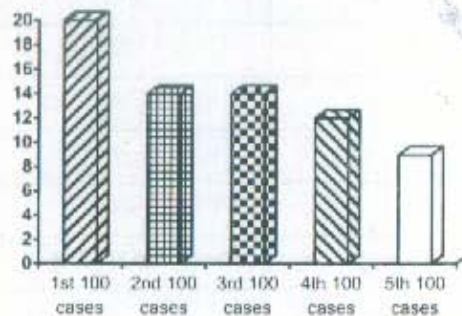


Fig 4: Rate of intra operative complications per 100 cases

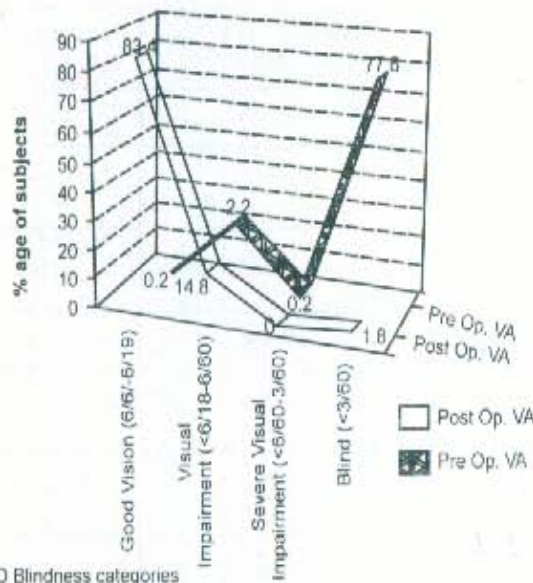


Fig. 5: Comparison of preoperative and postoperative visual acuity (VA)

More than 70% of the study subjects had a pre-operative visual acuity of less than 3/60. We found ocular comorbidity in more than 12% of cases. As the fundus can not be visualised, usually it is difficult to make a preoperative diagnosis of glaucomatous neuropathy, ARMD or diabetic retinopathy. The prevalence of ocular comorbidities can be compared with 28% comorbidity of cataract patients in United Kingdom¹⁶ and 8.2% of patients at Kikuyu⁷. The higher prevalence of ocular comorbidity may be due to increased longevity and greater probability of

diabetes and its complications in UK patients. We did not exclude these patients from the study, which definitely affected the final visual outcome. Hennig et al did not include these cases in the study¹³.

Sutureless cataract surgery is more difficult than conventional sutured extracapsular cataract extraction with PC IOL. The construction of a relatively long and narrow scleral tunnel, handling the instruments, and removing the entire nucleus, all requires good surgical skills and additional training. However, once the technique is mastered, the surgery is faster and less expensive, because no sutures are used. When performed by an experienced surgeon, the complications rate is low. In this study the complications rate decreased gradually as the surgeon overcame the initial hiccups associated with the learning curve. The graphic presentation of complications shows decline of surgical complications in the successive hundred cases. Hyphaema was the most common operative complication in our series, which occurred in 58(11.6%) cases of the study subjects. Reported incidences of hyphaema usually ranges from 9.4%¹³ to 34%¹⁷ in other international studies. This occurred as a result of surgical trauma to the perforating vessels in spite of moderate cautery before or during the tunnel construction.

Iridodialysis was the second common intra operative complication occurring in 7.2% of cases. This cannot be compared to Gogate et al¹⁸ who described Iridodialysis in only 2(0.55%) cases. This was because of premature entry in to anterior chamber in the early learning curve phase and repeated attempts to reposit the prolapsed iris during surgery.

Seventy eight (15.6%) out of 500 patients had a postoperative complication event in the first week of follow-up, while Gogate et al¹⁸ had such complications in 121 of 358 patients. We faced hyphaema as the most common postoperative complication followed by striate keratopathy. While Hennig¹³, reported hyphaema in 19 patients out of his 500 series. Difficulty in tunnel construction in the early phase of learning curve and dissection of perforating veins in the operation field were the main factors for postoperative hyphaema.

However the hyphaema present in our patients on first visit was often transient and absorbed well within 3-4 days. Only 4 cases required second intervention to wash the hyphaema. Striate keratopathy was seen in 5% of patients, which was less than Singh and Kaur¹⁵ who used Singh vectis for removing the nucleus.

The nonuse of any additional instrument for removing the nucleus, or cutting the nucleus into pieces in anterior chamber may be the cause of low incidence of striate keratopathy in our cases.

A total of 412 (82.80%) patients presented for follow up after 6 weeks. This can be compared to Yorston et al¹ study where 67.25% patients presented for 2 months follow up. Eighty eight (17.2%) patients did not respond to follow up probably because they belonged to remote parts of the province and follow up was not possible. Another reason for not presenting for follow up may be that majority of them had a good vision on first week follow-up.

Uncorrected visual acuity of 6/6-6/18 was achieved at the end of first postoperative week in 83.40% of patients. Only 14.8% of the patients were in the visual impairment category. At the end of 6th week follow-up the uncorrected visual acuity of 6/6-6/18 was achieved in 76.2% of patients. Out of 17.2% non-responders, 67(77%) were in good vision category (6/6-6/18) on first week follow-up. If these good vision category patients are included into 76.25% of good vision category after 6 weeks follow up, it makes altogether 89.6% of patients in good vision category. The result of visual rehabilitation can be compared well with Pratab¹⁹ and Hennig¹³. Their results show uncorrected acuity of 6/18 or better in 80 % and 76.8% respectively after 3 and 6 weeks follow-up. The visual recovery can also be compared with other studies. By comparison in a randomized controlled trial of standard ECCE and PC IOL and intracapsular cataract extraction and aphakic glasses only 57.5% of ECCE and PC IOL eyes achieved an unaided acuity of 6/18 or better 2 months after surgery²⁰. However another study of sutureless cataract surgery in Nepal¹⁰ and Ghana ²¹ showed that only 58.3% and 72% of eyes obtained an uncorrected vision of 6/18 or better at the end of 8 weeks after surgery.

The mean induced astigmatism of 0.33 D and 0.23 D at one week and 6 weeks follow up can be compared well with other reports. Mean surgically induced astigmatism found by Sood A et al²², Singh G¹⁵, Hennig et al¹³ and Ruit et al¹⁰ was 1.46 D, 1.62 D, 1.40 D and 1.9 D respectively. This shows that there is no major effect of astigmatism on final visual outcome in our study. As there is decrease in astigmatism and increase in unaided visual acuity at 6 weeks follow up, suggesting that the wound is stable by the end of 6 weeks after surgery.

These results would have been improved by best correction. For those patients where it was less than

baseline, the cause was not related to surgical procedure. Other co-morbidities like diabetic retinopathy, glaucoma, age related macular degeneration and corneal opacities were instrumental in very severe visual impairment and blind category cases.

CONCLUSIONS

MSICS is a sutureless, repeatable and relatively easy surgical method which can be used for any type of cataract from soft to rockhard cataracts. The wound is more secure with reduced intraoperative complications and virtually no chance for expulsive haemorrhage.

So far our experience has shown that the final visual outcome of the manual small incision cataract surgery has been very encouraging with a minimum vision threatening complications. We have found that this technique is a good alternative to phaco emulsification surgery in developing countries. It enjoys all the advantages of modern phaco surgery and also serves as a step stone for those who wish to convert to phaco emulsification technique. As majority of Ophthalmologist in developing countries are being trained in conventional ECCE surgery, it is easy to convert to MSICS than to phacoemulsification, as anterior chamber dynamics in MSICS are similar to conventional ECCE. It can be a safe and effective technique in the hands of an experienced surgeon in areas with a high demand for cataract surgery including advanced cataracts with a large nucleus.

This technique needs patronage for adoption in the community eye care settings, which will definitely improve the quality of cataract surgery and will have positive implication on final visual rehabilitation of cataract patients. Further, more improved trials are needed to provide better evidence of cost, risks and benefits.

Author's affiliation

Dr. Mir Zaman
Senior Registrar
Department of Ophthalmology
KIOMS, HMC
Peshawar.

Dr. Sofia Iqbal
Department of Ophthalmology
KIOMS, HMC
Peshawar

Dr. Muhammad Younas Khan
Consultant Ophthalmology
Department of Ophthalmology
KIOMS, HMC, Peshawar

Dr. Muhammad Tariq Khan
Department of Ophthalmology
KIOMS, HMC
Peshawar

Dr. Muhammad Zahid Jadoon
Department of Ophthalmology
KIOMS, HMC
Peshawar

Dr. Muhammad Babar Qureshi
Department of Ophthalmology
KIOMS, HMC
Peshawar

Dr. Muhammad Aman Safi
Department of Ophthalmology
KIOMS, HMC
Peshawar

Prof. Muhammad Daud Khan
Professor of Ophthalmology
KIOMS, HMC
Peshawar

REFERENCE

1. Yorston D, Gichuhi S, Wood M, et al. Does prospective monitoring improve cataract surgery outcomes in Africa. *Br J Ophthalmol.* 86:543, 1-11.
2. Foster A. Cataract-a global perspective: output, outcome and outlay. *Eye* 1999; 12:449-53
3. Limburg H, Foster A, Gilbert C, et al. Kyndt Routine monitoring of visual outcome of cataract surgery. *Br J Ophthalmol.* 2005; 89:45.
4. Sing AJ, Garner P, Floyd K. Cost effectiveness of public funded option for cataract surgery in Mysore, India. *Lancet* 2000; 355:180-4.
5. Johnson GJ. Improving outcome of cataract surgery in developing countries. *Lancet* 2000; 355:158-9.
6. Wong TY. Cataract extraction rates among Chinese, Malays and Indian population in Singapore, A population based analysis. *Arch Ophthalmol.* 2001; 119: 727-32.
7. Gupta AK, Tiwari HK, Ellwein LB. Cataract survey of India- Results of 1995 survey of Ophthalmologist. *Ind J Ophthalmol.* 1998;46: 47-50.
8. El Maghraby A, Anwar M, El Sayyad F, et al. Effect of incision size on early post operative visual rehabilitation after cataract surgery and intra ocular lens implantation. *J Cataract Refractive Surg* 1993; 19:494-8.
9. Mishra P. Small incision cataract surgery. *Indmedica-cyber lectures*, 2003; 1-4.
10. Ruit S, Paudyal G, Gurung R, et al. An innovation in developing world cataract surgery: Sutureless extracapsular cataract extraction with intraocular lens implantation. *Clin Experiment Ophthalmol.* 2000; 28: 274-9.
11. Schroeder B. Sutureless cataract extraction complications. Management and learning curves. *Community Eye Health* 2003; 16; 48:58-60.
12. Gogate P. clinical trial of manual small incision cataract surgery and standard ECCE. *Community Eye Health* 2003; 48: 54-5.
13. Hennig A, Kumar J, Yorston D, et al. Sutureless cataract surgery with nucleus extraction: outcome of a prospective study in Nepal. *Br J Ophthalmol.* 2003; 87: 266-70.
14. Lewis A, Congdon N, Munoz B, et al. cataract surgery and subtype in a defined, older population: The SEECAT project. *Br J Ophthalmol.* 2004; 88:1512-7.
15. Singh G, Kaur J. Manual Small Incision Sutureless Modified Phaco-sandwich. Technique Using Singh Vectis. *Am J Ophthalmol.* 2001; 3:
16. Desai P, Reidy A, Minassian DC. Profile of patients presenting for cataract surgery in the UK: national data collection. *Br J Ophthalmol.* 1999;83: 893-6.
17. John ME, Noblitt RL, Boleyn KL, et al. Effect of a superficial and a deep scleral pocket incision on the incidence of hyphaema. *J Cataract Refract Surg* 1992; 18: 495-9.
18. Gogate PM, Deshpande M, Wormald RP, et al. Extracapsular cataract surgery compared with MSICS in Community eye care setting in western India: a randomized controlled trial. *Br J Ophthalmol.* 2003; 87: 667-72.
19. Pratap VP, Bali T. Non Phaco-sutureless cataract surgery-an easy technique using "fish hook" AIOC proceedings 2002;182-3.
20. Prajna NV, Chandravanth KS, Kim R, et al. The Madurai intraocular lens study II: Clinical outcomes. *Am J Ophthalmol.* 1998; 125: 14-25.
21. Guzek JP, Ching A. Small incision manual extracapsular cataract surgery in Ghana, West Africa. *J Cataract Refract Surg.* 2003; 29:57-64.
22. Sood A, Kumar S, Badhu B. Astigmatism and corneal thickness in conventional large incision versus Manual small incision cataract surgery. *Asian J Ophthalmol.* 2002; 4: 2-6.